

Inadvertent Ocular Perforation during Lid Anesthesia for Hordeolum Removal

Jun-Heon Kim, MD, Sun Mo Yang, MD, Hyo Myung Kim, MD, PhD., Jaeryung Oh, MD, PhD.

Department of Ophthalmology, Korea University College of Medicine, Seoul, Korea

Purpose: Ocular perforation during lid anesthesia is rarely reported. We describe here a case of inadvertent corneal perforation and traumatic cataract that occurred during lid anesthesia in a procedure for hordeolum removal.

Methods: A 33-year-old woman presented with a sudden visual loss of her left eye. She had undergone hordeolum removal the day before at a local clinic. On ophthalmologic examination, the cornea was perforated and the lens cortex was extruded into the anterior chamber. After cataract removal and IOL implantation, antibiotics were injected into the vitreous.

Results: Her final visual acuity of the left eye was 20/20. Postoperative specular microscopic examination revealed a normal-range endothelial cell count, coefficient of variation, and hexagonality despite the intracameral lidocaine injection.

Conclusions: Anesthetic injection of an infected lid should be done with great caution. Although there are possibilities of corneal endothelial toxicity and endophthalmitis in case of intracameral lidocaine injection through the infected lid, yet proper management may save the patient's vision without complications. *Korean Journal of Ophthalmology* 20(3):199-200, 2006

Key Words: Hordeolum, Intracameral lidocaine, Lid anesthesia, Ocular perforation

Inadvertent ocular perforation is a well-recognized complication that can occur during retrobulbar and peribulbar block. However, ocular perforation during lid anesthesia, especially through the infected lid, has been rarely reported. We describe here a case of inadvertent corneal perforation and traumatic cataract that occurred during lid anesthesia in a hordeolum removal procedure.

Case Report

A 33-year-old woman who had undergone removal of a hordeolum in her left upper eyelid the day before was referred to our hospital. She presented with a sudden visual loss of her left eye. On ophthalmologic examination, the visual acuity of the left eye was finger counting and the cornea was perforated. Swelling of the left upper lid due to a hordeolum was also observed (Fig. 1A). The corneal wound had the appearance of a needle penetration with leakage at the 10 o'clock mid-peripheral cornea. The anterior lens capsule was ruptured and the lens cortex was extruded into the anterior chamber (Fig. 1B). The anterior chamber was

deep, despite the focal corneal leakage, and was filled with 1+ flare and 4+ inflammatory cells. The cataract was removed by aspiration. On the operative findings, the anterior lens capsule inside the pupil margin was ruptured. The iris and posterior lens capsule was intact and no vitreous was found in the anterior chamber. The hydrated lens cortex was removed and an intraocular lens was implanted into the capsular bag. For the prophylaxis of endophthalmitis, vancomycin and amikacin were injected intravitreally. Because the depth of the anterior chamber was maintained and no active leakage was observed during the operation, a pressure patch was applied without further treatment for the corneal wound. On the first postoperative day, the patient's visual acuity was 20/40 and there was no leakage from the perforated corneal wound. No organism was identified from the stain and 2-day culture of the preoperative conjunctival swab, and no infectious complication occurred thereafter. At 1 month postoperatively, the corrected visual acuity was 20/20 and the endothelial cell count was 2954/mm² with a normal coefficient of variation (CV) and hexagonality.

Discussion

Global penetration is acknowledged to be a complication of retrobulbar or peribulbar block, although the risk is less than 0.1% in normal axial length.¹ In these cases, visual morbidity is related to the type of posterior segment injury,

Received: March 13, 2006 Accepted: July 7, 2006

Reprint requests to Jaeryung Oh, MD, PhD. Department of Ophthalmology, College of Medicine, Korea University, #126-1 5Ka, Anam-Dong, Songbuk-Ku, Seoul 136-705, Korea. Tel: 82-2-920-5520, Fax: 82-2-924-6820, E-mail: ojr4991@yahoo.co.kr

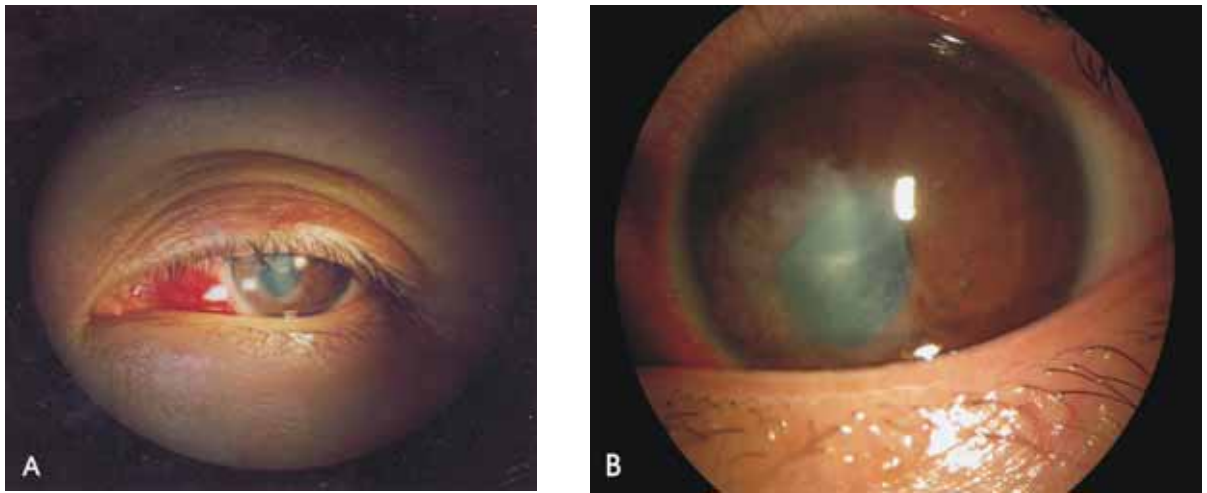


Fig. 1. (A) Swelling of the left upper lid due to a hordeolum. (B) The anterior lens capsule was ruptured and the lens cortex was extruded into the anterior chamber with a penetrating corneal wound at the 10 o'clock mid-peripheral cornea.

which can include vitreous hemorrhage, retinal detachment, and macular toxicity.

However, ocular perforation during lid anesthesia is rarely reported.² In our case, because the needle might have been inserted at an incorrect angle in the state with the eyelid closed, the cornea and anterior lens capsule were penetrated.

There are some differences between the case of ocular perforation during anesthesia for an inflamed lid and ocular injury incurred by retrobulbar or peribulbar block. Intraocular microbial inoculation via the needle that passes through the infected lid, such as a lid with a hordeolum, can induce intraocular infection. Since the primary sources of postoperative endophthalmitis are organisms on the ocular surface and adnexa, and hordeolums are primarily staphylococcal abscesses, endophthalmitis might have occurred in this case.^{3,4} In order to prevent endophthalmitis, we administered injections of prophylactic intravitreal antibiotics as per EVS protocol.⁵ It is not clear whether these injections were useful in this case of ocular perforation by a needle that passed through the lid. However, we thought them necessary due to the risk of endophthalmitis, because the lid was certainly infected and the needle had passed through it.

The lens cortex of this patient was hydrated and extruded into the anterior chamber, suggesting that some amount of anesthetic agent had been injected into the lens cortex. Intracamerally injected lidocaine may induce endothelial cell damage. Moreover, the preservatives in the lidocaine are also a potential risk factor of endothelial toxicity. Guzey M, et al.⁶ found corneal thickening and other evidences of endothelial dysfunction after intracamerally injected nonpreserved 2%